

Treatment of C4/C5, C5/C6 and C6/C7 Disc Herniations using Cox® Technic Protocols

by Dr. Mike M. Poulin, D.C.

Herndon, Virginia

Ashburn, Virginia



HISTORY

A 51 yr. old Caucasian female who is an Aesthetician presented to our office on 12/21/2006, with right sided neck and upper back pain with associated right arm numbness to 1st, 2nd and 3rd digit. She was referred to us by her neurosurgeon.

CHIEF COMPLAINTS

The patient describes neck/upper back pain as constant, ache with tightness during day and night while sleeping. The right arm radiculopathy is characterized as burning, tingling and numbness to 3rd digit and some 1st and 2nd digit. The neck pain is a “5-6” and right arm pain is a “9” on 0-10 V.A.S. The onset of pain occurred one month prior while in a dentist chair and has progressively gotten worse. The pain is increased with coughing, sneezing, bending, straining, and changing of positions. Night pain is also present. The pain is decreased with ice. Prior medical care includes the following:

- Neurosurgeon – 1 month prior to presenting to us
- Orthopedic surgeon - 1 week prior
- Neurosurgeon – Morning of her appt. with us.

Medical doctors had given her Percocet and methyl prednisone.

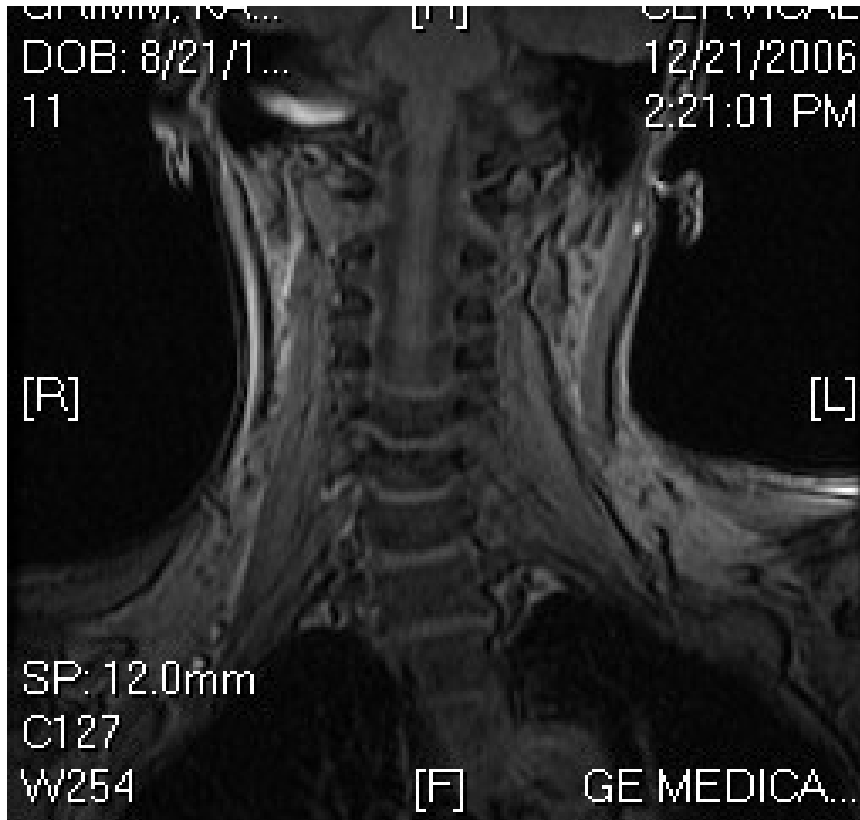EXAMINATION FINDINGS

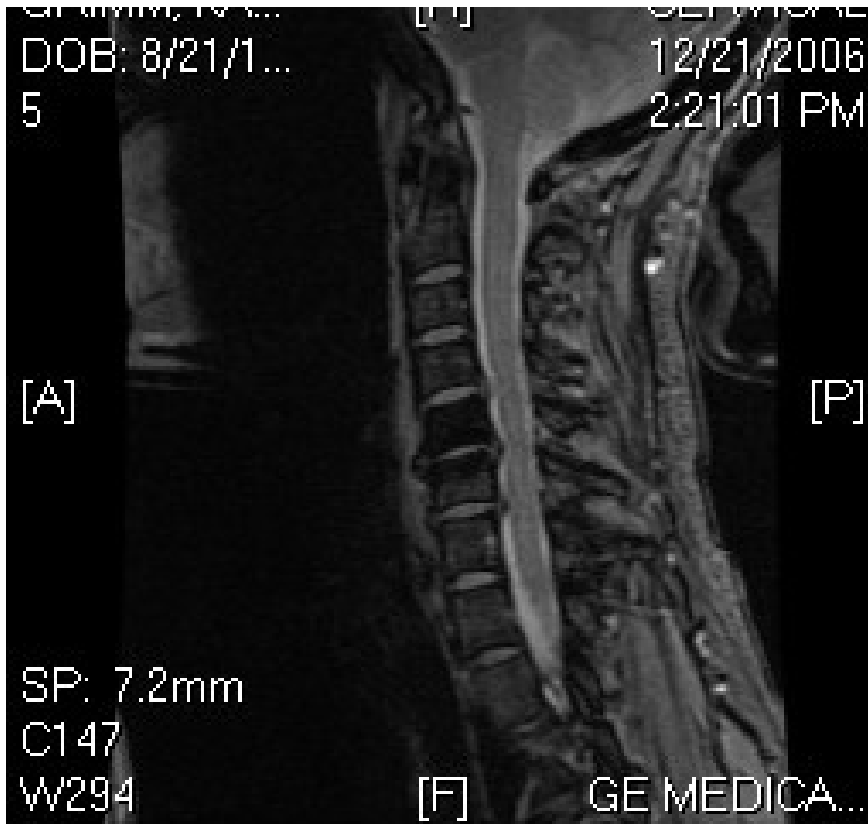
- Abnormal findings:
 - + Dejerine's Triad
 - + Cervical Compression
 - + Cervical R.O.M.
- All R.O.M. were very painful and limited especially in right lateral flexion.
 - C5, C6, C7, T1, T2 vertebrae and T1, T2 ribs had severe pain on palpation and percussion.
 - Severe muscle spasms are noted in the paraspinals and trapezius.
 - Right bicep is a “4” on a 0-5 muscle strength.

- There are normal Deep Tendon Reflexes. (ASK COX AND POULIN WHAT THIS MEANS!)

IMAGING

MRI - Cervical spine with scoliosis / list





MRI FINDINGS

- C4-C5: Central to left-sided disc herniation with mild CSF effacement. No evidence of neural foraminal narrowing. Mild left-sided uncovertebral joint hypertrophy.
- C5-C6: Broad-based central disc herniation with complete anterior CSF effacement and mild flattening of the cord. There is also mild left-sided neural foraminal narrowing. Normal signal within the cord, however.
- C6-C7: Central to right-sided disc extrusion with CSF effacement and flattening of the cord. Right-sided neural foraminal narrowing.
- C7-T1: Normal.

DIAGNOSIS

- 722.0 Cervical disc disorder
- 723.3 Cervical-brachial syndrome
- 737.30 Scoliosis
- 728.85 Muscle spasm

RECOMMENDATIONS

The treatment planned shared with the patient is for 4 appointments a week for 1 week then 3 a week for 3 weeks. I shared with her that we expect her to be 50% better by the

12th visit (50% Rule: 50% improvement subjectively and objectively in 30 days) and 75% by the 24th visit. The clinical goal is to decrease the VAS by 50% in neck and arm pain, increase R.O.M., and allow her to cough and sneeze with no pain. The treatment visit goal is to reduce treatments to one visit every three weeks.

TREATMENT PLAN

The patient brought in Cervical MRI's done that morning after the neurosurgeon called us to get her in ASAP. No xrays were taken at our office. After a thorough history and orthopedic, neurological & spinal exam, I consulted with the patient and gave a brief report of findings. I applied Cox® Disc Decompression with the Cox®7 Table's cervical headpiece after careful tolerance testing and applied gentle y-axis with left lateral flexion to reduce right arm radiculopathy. Post adjustment, electrical muscle stimulation was applied to the neck and arm dermatome. Home care was discussed which included ice application, sleep position, using a rectangular, latex cervical pillow (non-contoured), and taking Formula ONE (daily multi supplement), Formula #2 (Calcium Citrate with Vitamin D3 and Magnesium) and Discat Plus (glucosamine and chondroitin with other nutrients found in the disc).

OUTCOME

Now the patient comes in to be decompressed and adjusted once every 3-4 weeks. This keeps her feeling great and avoiding surgery. She states that "I can do my job with no pain. I am NOT IN PAIN." She was 75% better by 25th visit. She returned to the gym, and as a busy mother of 4 is able to get to kids' activities like the VA Tech Football games, etc. She feels great.

CONCLUSION

When treating the 1 out of 4 spine pain patients who account for 95% of the cost of spine pain management, effective means of treatment are essential. 90% of our clinic's patients get Cox® Technic adjusting. Cox® Technic is research-proven, clinically effective, hands-on chiropractic adjusting that helps patients return to their desired quality of life.